

Aesthetic Surgery Journal

<http://aes.sagepub.com/>

Complications of Injectable Fillers, Part I

Claudio DeLorenzi

Aesthetic Surgery Journal 2013 33: 561

DOI: 10.1177/1090820X13484492

The online version of this article can be found at:

<http://aes.sagepub.com/content/33/4/561>

Published by:



<http://www.sagepublications.com>

On behalf of:



[American Society for Aesthetic Plastic Surgery](#)

Additional services and information for *Aesthetic Surgery Journal* can be found at:

Email Alerts: <http://aes.sagepub.com/cgi/alerts>

Subscriptions: <http://aes.sagepub.com/subscriptions>

Reprints: <http://www.sagepub.com/journalsReprints.nav>

Permissions: <http://www.sagepub.com/journalsPermissions.nav>

>> [Version of Record](#) - May 1, 2013

[What is This?](#)

Continuing Medical Education Article

Complications of Injectable Fillers, Part I

Claudio DeLorenzi, MD, FRCS

Aesthetic Surgery Journal
33(4) 561–575
© 2013 The American Society for
Aesthetic Plastic Surgery, Inc.
Reprints and permission:
[http://www.sagepub.com/
journalsPermissions.nav](http://www.sagepub.com/journalsPermissions.nav)
DOI: 10.1177/1090820X13484492
www.aestheticsurgeryjournal.com


Abstract

Dermal filling has rapidly become one of the most common procedures performed by clinicians worldwide. The vast majority of treatments are successful and patient satisfaction is high. However, complications, both mild and severe, have been reported and result from injection of many different types of dermal fillers. In this Continuing Medical Education review article, the author describes common technical errors, the signs and symptoms of both common and rare complications, and management of sequelae in clear, easily adaptable treatment algorithms.

Keywords

filler complication, hyaluronidase, dermal filler technique, filler technique, biofilms, filler infection

Accepted for publication December 19, 2012.

Bovine collagen injections were popularized years ago, beginning with Zyderm collagen (Allergan, Inc, Irvine, California) in 1981. Since that time, numerous other products have come to market, the most popular of which are the hyaluronic acid (HA) products (Table 1). Hyaluronic acid products are linear, unbranched, high molecular weight glycosaminoglycan complex sugars, consisting of alternating d-glucuronic acid and N-acetyl-d-glucosamine. First described by Meyer and Palmer¹ in 1934 during analysis of bovine vitreous, HA is found in the skin and tissues and performs several functions, both physical (eg, lubrication) as well as chemical (as an essential substrate for many different biological processes, including fertility, embryogenesis, morphogenesis, cellular migration, inflammation, and wound healing).² In its natural state, HA is an ideal filler material but has an exceptionally short half-life.^{3–10} Manufacturers have altered the chemistry of HA by crosslinking chains (using various plasticizers such as butanediol diglycidyl ether [BDDE]¹¹) to retard natural turnover and increase half-life. By minimally altering the material, manufacturers have been able to create HA products that are well tolerated by the immune system and exhibit favorable properties of longevity and nonre-activity.

Early HA manufacturing attempts used animal-sourced raw materials and were plagued by protein contamination issues.¹² As a result, commercial sources of hyaluronates were developed from Lancefield group A and C *Streptococcus*

equi zooepidemicus, which naturally produce a pure hyaluronate mucoid capsule. Large quantities of relatively pure hyaluronates could thus be manufactured from bacterial broths that only required purification of relatively primitive bacterial protein contaminants, rather than the complex proteins that contaminated mammalian or avian sources. Attempts to prolong HA longevity in tissues by creating products with more crosslinks between chains resulted in a net decrease in tissue tolerance because of an increase in immune-mediated adverse events (AE). Thus, a balance was necessary whereby natural HA chemical structure was altered enough from its natural state to reduce its susceptibility to breakdown but was not so deviant as to be recognized by the immune system as foreign material.

Although HA remains the dominant filler product for volumizing tissues, other materials are available as well.¹⁰ Permanent dermal fillers include silicone oils, polymethyl methacrylate (PMMA) microspheres, polyacrylamide, and several other materials either alone or formulated in various combinations with resorbable components.^{13–18} The specific complications that may arise from each filler

Dr DeLorenzi is a plastic surgeon in private practice in Kitchener, Ontario, Canada.

Corresponding Author:

Dr Claudio DeLorenzi, 150 Edna Street, Kitchener, ON, N2H 6S1, Canada.

E-mail: fillercomplication@gmail.com

Table 1. Dermal Fillers Approved by the FDA Since 1981

		Reversible			
		Irreversible	Synthetic	Natural Source	
Major component	Polymethylmethacrylate (PMMA) ^a	Hydroxylapatite ^b	Poly-L-lactic acid (PLLA) ^c	Hyaluronic acid ^d	Collagen ^e
Year first approved	2006	2006	2004	2003	1981
Brand name (manufacturer)	Artefill (Suneva Medical, San Diego, California)	Radiesse (Merz Aesthetics, San Mateo, California)	Sculptra (Valeant, Bridgewater, New Jersey)	Restylane, Perlane (Q-Med [Uppsala, Sweden]/Valeant [Bridgewater, New Jersey])	Zyderm, Zyplast (Allergan)
				Hylaform, Hylaform Plus (Genzyme Biosurgery, Ridgefield, New Jersey)	Cosmoderm, Cosmoplast (Allergan)
				Juvéderm30, Juvéderm30HV, Juvéderm24HV (Allergan, Irvine, California)	Evolence (ColBar Life Science, Mattawan, Michigan)
				Eleveess (Anika Therapeutics, Bedford, Massachusetts)	

This table is not a complete listing of all products available. FDA, US Food and Drug Administration.

^aPoly(methyl methacrylate) (PMMA): a synthetic nonbiodegradable polymer also used in bone cement and synthetic intraocular lenses. It is formulated in 40-micron microspheres suspended in bovine collagen.

^bCalcium hydroxylapatite: mineral typically found in teeth and bone. Reconstituted as a gel suspension and injected. Lasts approximately 18 months.

^cPoly-L-lactic acid: a slowly biodegradable polymer that has been used in suture materials for many years. Results may last up to 2 years, depending on site of injection.

^dHyaluronic acid: polysaccharide that binds water and is sourced from avian (eg, rooster combs) or streptococcal bacteria. The polysaccharide is crosslinked to resist degradation, extending its durability from 6 to 18 months, depending on formulation and region injected.

^eCollagen: protein derived from cow (bovine) or human cells, lasting 3 to 4 months, the shortest duration of any of the dermal fillers. Collagen products have been discontinued and are no longer available.

Table 2. Filler Complication Classifications

Type	Description
Technical errors	a. Volume (too much or too little)
	b. Depth (too superficial or too deep)
	c. Location (wrong location)
	d. Product choice (inappropriate product)
Inflammatory	a. Infectious agent (bacterial, fungal, viral, or biofilm mediated)
	b. Immune mediated (not related to infectious agent)

subtype will be ignored for the purposes of this article, and general types of complications will be discussed instead (Table 2). In terms of a generic classification of dermal fillers, it is helpful to separate them into 2 main classes: reversible and irreversible¹⁹ (rather than temporary vs permanent). Hyaluronic acid fillers are examples of reversible dermal fillers because they may be completely removed with the use of hyaluronidase.¹⁹⁻²⁷ Because of the overwhelming popularity of HA fillers, the bulk of this Continuing Medical Education review article will address HA filler complications and summarize clinical case reports, both in the medical literature and those seen by the author in cooperation with manufacturers, other clinicians, and by referral.

TECHNICAL AESTHETIC COMPLICATIONS

As with any complication in medicine, avoidance is far preferable to management. Fillers are classified by the US Food and Drug Administration (FDA) as devices, not medications. Therefore, the same precautions taken with other implantable devices apply with dermal fillers. However, the occurrence of posttreatment complications in some patients is inevitable. Reversible HA fillers have the very beneficial quality of responding to hyaluronidase, which allows the physician to simply remove all injected material and start over at a later time. The following complications can be addressed relatively easily if they result from reversible fillers:

1. Volume: too much or too little filler
2. Depth of treatment: filler injected too superficially or too deep
3. Location: unfavorable anatomic location or asymmetry, or injection into the incorrect anatomical location

Problems with irreversible fillers are much more difficult to manage, especially if vital structures have been treated. Excision of filler product²⁸⁻³² may be possible in some areas without causing too much damage to vital structures and minor errors of symmetry or insufficient volume may be addressed by adding more product, but

irreversible fillers cannot easily be removed. Therefore, the author strongly recommends that they not be considered as a first-line choice and should be used only by clinicians with substantial training and experience with these filler agents. Even in the best hands, complications may occur, and this calls for extreme caution, especially when injecting the product around vital facial structures.

Dermal fillers of chemically different families generally should not be injected into the same anatomic location because it may obfuscate any attempt to correlate an adverse reaction with its causative filler. Although literature support for this hypothesis is scant,³³ the author's clinical experience suggests that HA fillers injected over irreversible fillers (eg, PMMA) may exacerbate/stimulate nodule formation. This may be related to the biofilm hypothesis,³⁴⁻³⁹ which will be discussed later, or to some as yet unknown process. A patient registry failed to illustrate an increased risk of nodules from filler mixing, but the sample size was small and the data set regarding the fillers administered was incomplete.⁴⁰

Factors that may play an important role in the development of foreign body reactions include particle size and degree of smoothness,⁴¹ chemical composition, surface charge,⁴² particle concentration, immunogenicity, and hydrophilicity.³⁸ When we add to these the multiplicity of chemical and physical interactions possible between materials of differing chemical composition that may occur when these materials are simultaneously injected into the same area, we make the task of trying to isolate causal factors ever more difficult. The author believes that some patients with whom he has consulted regarding this phenomenon experienced complications related to the introduction of small numbers of bacteria (particularly atypical organisms, such as mycobacteria) into an area with an existing dermal implant (foreign body), which is consistent with the biofilm hypothesis. Before describing the most commonly seen categories of dermal filler complications and suggesting strategies for management that have been useful in clinical practice, it may be helpful to review the properties of hyaluronidase.

Hyaluronidase

Hyaluronidase (HYAL) is a mucolytic enzyme that hydrolyzes both natural and crosslinked HA dermal fillers. Just as HA appears in so many areas of the human body, HYAL is also thought to play important roles in many natural biochemical processes⁴³ and has proven useful in clinical medicine. It has been applied, for example, in the dispersion of local anesthetics,⁴⁴ administration of resuscitation fluids by hypodermoclysis,⁴⁵ and fertility studies.⁴⁶⁻⁴⁸ Hyaluronidase was initially isolated from microorganisms and subsequently from bovine testis and most recently by recombinant technology. The biology of HA metabolism is far from being completely understood in animal models, let alone in humans.⁴⁹ Furthermore, HYAL is not a single moiety; rather, it represents a family of compounds with similar but not identical effects in mammals.^{2,50} There are 3 distinct groups of HYAL: (1) mammalian, (2) bacterial, and (3) from

leeches, crustaceans, and some parasites.² Different formulations of HYAL are available for clinical use in different countries, which makes it difficult to describe the correct use of these various products, since activity level varies by type, pH, and a host of other biochemical factors. In some countries, there are no commercial, "pharmaceutical grade" sources of HYAL available. Clinicians in these countries obtain HYAL from compounding pharmacies, from which product variation in purity, stability, and effectiveness creates even more problems for the clinician. Comments in the literature about the dosage, dilution, and subsequent effectiveness of HYAL must be tempered by the understanding that the source of the product is likely unknown, unless it is specified in the article.

Hyaluronidase of the mammalian type generally splits naturally occurring HA into smaller oligomers (mainly hexasaccharides).² However, the biochemical interaction between HYAL and commercially sold, crosslinked HA may be altogether different. The amounts, dilution, and method of administration can thus only be discussed with respect to the specific agent being injected. The literature offers several examples of widely divergent doses, but the author recommends that the actual quantity administered be titrated to effect—that is, to use as much as necessary to achieve the desired clinical results. If there is no history of patient allergy to HYAL or to any of the ingredients, the author uses a starting dose of 150 IU but has also injected up to 1500 IU in cases of vascular compromise. It is important to keep in mind the distinction between animal-sourced and recombinant human HYAL since the associated animal protein in the former may be a source of grief and consternation (causing unintentional immune mediated reactions in some patients).

Hyaluronidase may be diluted with local anesthetics or normal saline, but it is crucial to be watchful of the pH of various diluents since it may adversely affect the efficiency of HYAL. It may be injected directly and slowly into the affected site to initiate hydrolysis of the previously injected HA. Injecting a small amount of suitable local anesthesia will facilitate massage, which is very important in obtaining the therapeutic effect. The nature and quality of the dermal HA filler product are an important consideration for the effectiveness of HYAL. For example, if a particulate form of dermal filler is used (eg, Restylane; Q-Med, Uppsala, Sweden; distributed in North America by Medicis Aesthetics, Scottsdale, Arizona), HYAL can quickly surround the granules of heavily crosslinked HA and hydrolyze the material over a broad surface area, several orders of magnitude larger than that of monophasic products (eg, Juvéderm; Allergan, Inc). The latter takes significantly longer to clinically disperse than the former, presumably because of this fundamental biochemical difference. The Restylane family of products is generally produced by creating a crosslinked matrix, which is subsequently separated into particles that are then suspended and lubricated by minimally or completely non-crosslinked HA. The non-crosslinked HA fraction responds immediately (in seconds to minutes) to HYAL, allowing it to surround the small particles. With the Juvéderm family of products, HYAL can only affect the outermost surface of the aliquot, taking far longer to break down the HA. In the author's experience,

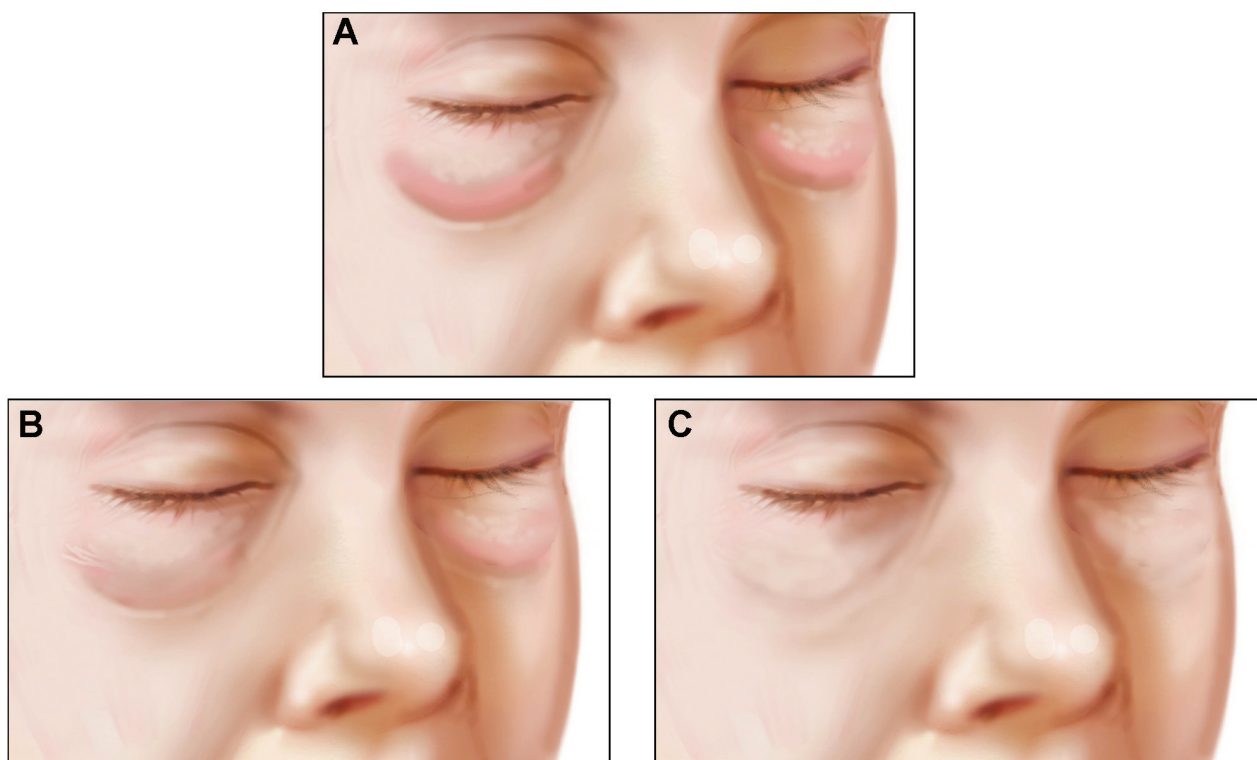


Figure 1. (A) Typical appearance following accidental retroseptal injection of hyaluronic acid (HA)-based filler product, which may occur when treating the nasojugal area if injection accidentally penetrates the orbital septum. The HA material causes persistent nonpitting edema of the inferior periorbital area. (B) Typical appearance immediately following initial treatment with hyaluronidase and gentle massage for correction of retroseptal injection. Note the rapid resolution of edema of the inferior orbital area (above the orbital rim). (C) Typical appearance approximately 1 week posttreatment.

massage is essential to mechanically mix the HYAL with the HA and promote hydrolysis in the clinical setting. The author tested these principles *in vitro* in unpublished work and found that the same phenomenon was easily demonstrable; granular product liquefied very quickly, whereas monophasic product took far longer. Readers are encouraged to verify the veracity of this phenomenon with their own HA filler products, since it is both instructive and has direct clinical application.

Formerly, most HYAL preparations were animal-sourced products, and the literature offers several examples of allergic phenomena occurring in patients treated with retrobulbar blocks associated with ophthalmic surgery.⁵¹⁻⁶⁵ Anaphylaxis has been described following HYAL administration,^{62,66-68} although this appears to be rare and was likely due to bovine serum proteins in the preparations⁶⁵; reaction may occur even in patients with no known previous exposure. The venom of stinging insects may contain HYAL, and this mechanism may be the source of sensitization in affected individuals.

Hyaluronidase has proven very helpful in the management of many of the complications that may arise from the injection of HA-based dermal fillers.* Clinicians are

encouraged to have it readily available to treat asymmetry or unfavorable cosmetic outcomes after HA injection, especially in urgent or emergency situations such as impending necrosis due to vascular compromise.

Retroseptal or Premalar Filler Injection

As filling of the infraorbital region (nasojugal area) has become more popular,^{69,81,82} there has been an increase in accidental retroseptal injection (Figure 1). A similar phenomenon may occur with injections anterior to the orbitomalar septum, as described by Pessa et al,^{83,84} resulting in troubling, persistent premalar edema. The orbital septum may accidentally be penetrated when injecting into the infraorbital area, where filler product may be injected behind the orbital septum or anterior to the orbitomalar septum.⁸⁵ This may occur when the injector treats too high, treats too close to the infraorbital rim, injects too deep, accidentally penetrates the septum, or simply injects too much product when the integrity of the septum has been previously breached (as with a popular fat repositioning type of blepharoplasty). This results in the appearance of sometimes dramatic eyelid bags where none existed prior to filler treatment. A similar phenomenon occurs with superficial injections of material anterior to the malar septum, which results in severe premalar edema.

*References 19, 20, 22, 24, 26, 27, 35, 69-80.

After making the diagnosis, treatment of these improper injections consists of careful injection of HYAL into the area⁶⁹ and subsequent massage to diffuse the HYAL and bring it into contact with the injected filler. A thorough understanding of the anatomy of each region treated with HA is important and is especially crucial with these injections, as the septum may dip below the bony infraorbital margin.⁸⁶⁻⁸⁹ Hyaluronic acid binds to water,^{90,91} which may result in significant edema in the retroseptal soft tissues with only a tiny amount of misplaced filler. Good technique involves treating deep to the orbicularis muscle and orbitomalar septum and carefully approaching this area from below to avoid retroseptal injection^{69,81} or injection anterior to the orbitomalar septum,⁸⁵ which may cause premalar edema.

The author has conferred with several patients who experienced these complications after HA treatment and underwent months of ineffective treatment with cardiac drugs, powerful diuretics, compression, steroids, and other interventions. A small dosage of HYAL can sometimes result in dramatic and immediate improvement. Those who have been injected with calcium hydroxylapatite (Radiesse; Merz Aesthetics, San Mateo, California) may be treated with injections of sterile water or saline (with or without lidocaine for local anesthesia) along with massage to help to mechanically dilute the material. Permanent fillers are far more difficult to treat in the presence of these complications, and excision may be the only possible remedy in some cases. However, HYAL treatment may produce positive results and involves a gentle injection of 25 to 100 IU into the affected areas followed by gentle massage. Because of the great variability in the various formulations of HYAL available in different regions, many of which are compounded by local pharmacies, it is best to treat to effect, rather than by absolute dosage. In other words, physicians should inject as much HYAL as required to achieve the desired effect. Although both naturally occurring, resident HA as well as artificial HA are affected by HYAL, the former is more sensitive than the latter because artificial HA is always crosslinked to various degrees. It is also important to remember that particulate forms of HA derivatives (such as the Restylane family of products) respond at a faster rate than the monophasic types (such as Juvéderm).

Tyndall Effect

The Tyndall effect (Figure 2) results from injection of HA fillers too close to the surface of the skin, which yields a “bluish” discoloration that may be readily treated with HYAL.^{23,92-94} The HA filler causes discoloration due to the refraction of light, so that melanin deep in the dermis displays a blue tint, resulting in “Mongolian spots.” The Tyndall effect looks somewhat like a mild but deep bruise (with which it may often be confused); it does not change over time until the material is removed.

Treatment of the Tyndall effect consists of HYAL injection into the surrounding tissues and subsequent gentle massage.^{23,92,94} The amount of HYAL that should be injected is not standardized, but the author’s personal experience suggests that 15 to 50 IU produces a good result. Clinical judgment should be exercised while dosage

is titrated to effect, again based on varying HYAL formulations. Massage of the material is essential to increase the effect of the enzyme. Only modest pressure is required, and simply rolling a cotton-tipped swab over the tissues is sufficient to disperse HYAL over the area.

Lumps and Nodules

Lumps and nodules can be caused by almost any filler when too much is injected into a small area, for a variety of reasons (Figure 3).^{30-32,35,37,39,95-127} For example, if the syringe is “sticky” and the injector places too much pressure on the plunger, a sudden release may accidentally dispense more filler than intended. The resulting lump or nodule is usually easily treated with a simple incision and drainage using a sharp disposable needle (Figure 3).

If nodules due to excess product are multiple or deep, a formal incision and drainage may not be feasible. In such cases, HA products can be treated with HYAL. Capsular contracture around tissue fillers is quite rare, but the author has seen and treated these on occasion. If a large amount of filler has been injected into an area with the “lake technique,” the resulting rare complication may present as a nodule or lump that becomes increasingly prominent as contraction of the capsule creates a spherical shape (analogous to a hardening breast implant capsule). The sphere is formed to hold the largest volume relative to the least surface area, which creates the deformity. This capsule may cause the patient pain and discomfort. A small amount of local anesthesia may be needed to pass a larger-bore needle or 16-gauge Luer-Lok syringe to break through the capsule and aspirate the material within. Hyaluronidase may be administered to clean up whatever remains behind. It may also be administered to attempt to treat nodules that are not responding to aspiration, even in patients who were injected with a material of unknown origin. (It should be noted that patients are only rarely aware of the products they received, and some may not even remember the name of the physician who originally injected them.) Hyaluronidase should be used with caution if infection is suspected, since this may result in spreading of the infection to surrounding areas. Nodules caused by other types of dermal fillers have varied etiology, including incorrect dilution or reconstitution, or incorrect placement or technique.[†] Simple excision may suffice in straightforward cases, but multiple nodules within vital anatomic structures pose great challenges to surgeons, and often call for unique methods of treatment (Figure 4).¹²⁸

INFLAMMATORY COMPLICATIONS

Infection

Infection following filler treatment is uncommon¹²⁹ but may be caused by bacterial, viral, and *Candida* species,

[†]References 98, 101, 104, 119, 121, 122, 125.

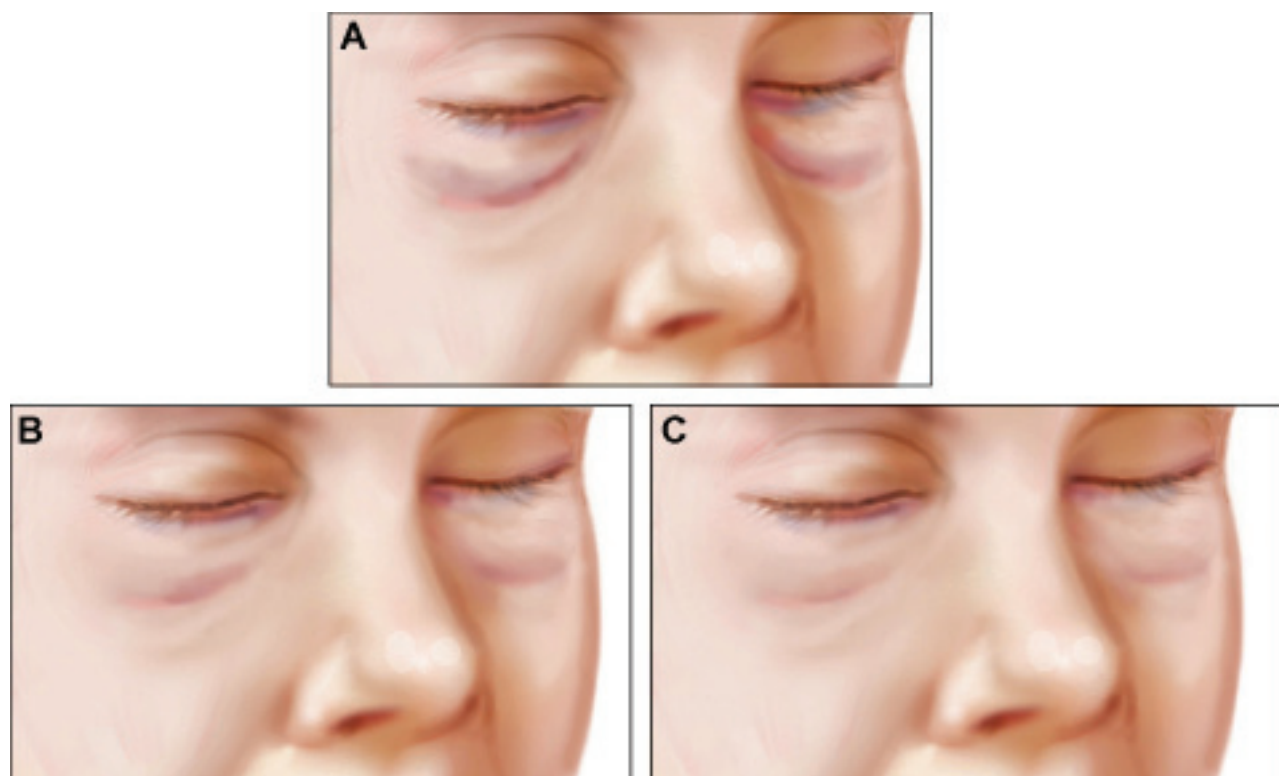


Figure 2. (A) Typical appearance of the Tyndall effect following hyaluronic acid injection. The “bluish” discoloration may be confused with persistent bruising in the periorbital tissues; it is also frequently seen in the nasolabial fold region. (B) Typical appearance immediately following treatment with hyaluronidase. (C) Typical appearance approximately 1 week posttreatment.

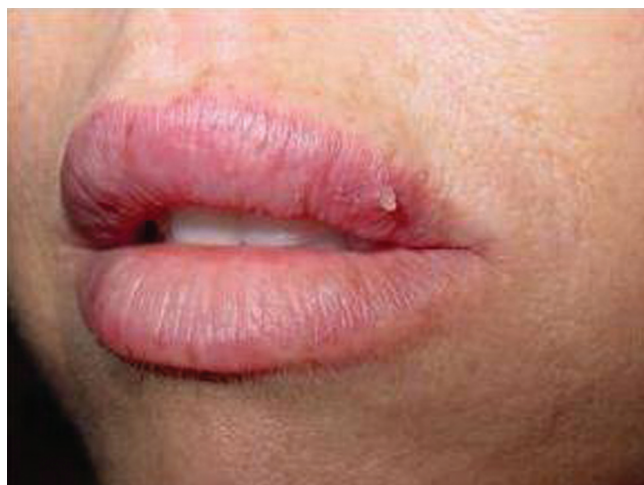

Figure 3. This 38-year-old woman presented with a submucosal nodule 1 month after hyaluronic acid filler treatment. Puncture (incision and drainage) was performed with a 21-gauge needle.

and it may sometimes occur as polymicrobial infection. The most common viral infection to occur in the skin after injection is herpes simplex. Patients with a strong history of cold sores or fever blisters may be pretreated with acy-

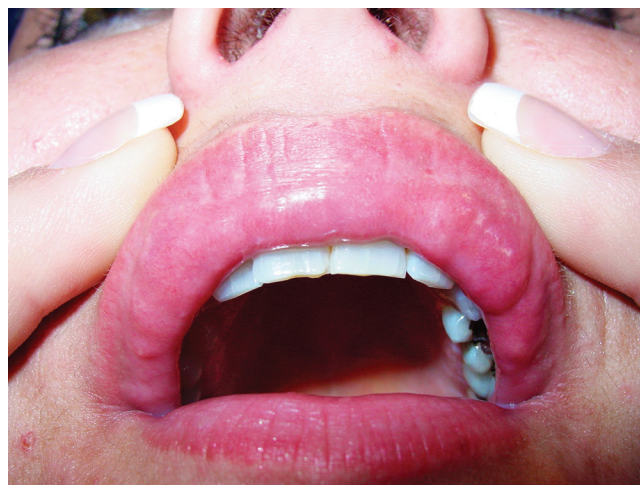

Figure 4. This 42-year-old woman received an inappropriate volume of PMMA-based permanent filler and presented to the author with multiple nodules along the vermilion. Biopsy confirmed 40 micron microspheres and no abnormal inflammatory response. Treatment options were limited and patient decided against surgical excision because of risk of scarring.

clovir, famciclovir, or valacyclovir to reduce the severity and duration of cutaneous herpes infections. If there is

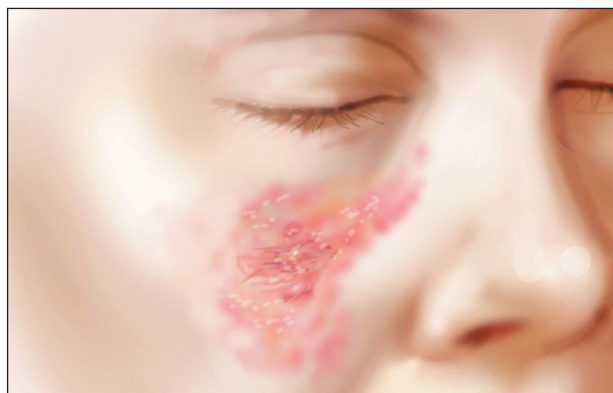

Figure 5. Herpes simplex type 1 may present as small, clear vesicles on the skin of the face a few days after filler treatment. The lesions often become secondarily infected with *Staph aureus* or Group A strep, leading to the relatively common presentation of impetiginized herpes simplex. Treatment typically consists of acyclovir and a cephalosporin as well as routine topical wound care. Note risk of confusion with vascular compromise. The timing of presentation is important, since vascular events begin at the time of injection, and herpetic lesions usually begin a few days after injection.

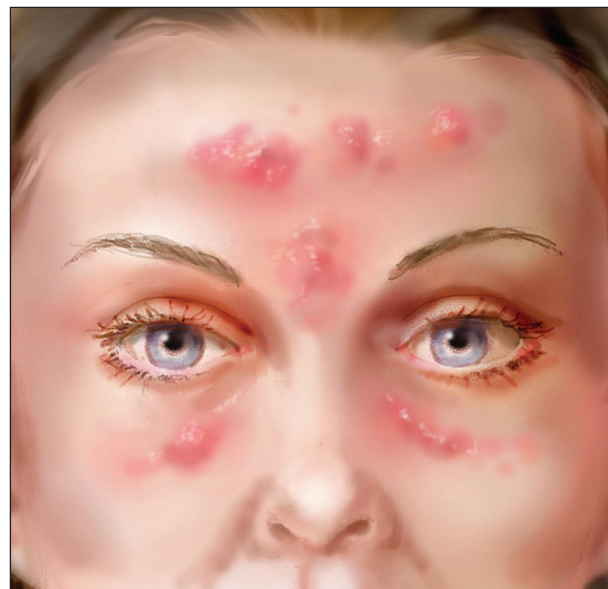


Figure 6. Subcutaneous abscesses such as those shown in this illustration can occur after injection of reformulated filler. Such abscesses are treated with incision and drainage.

any question of ocular infection, consultation with an ophthalmologist is recommended, since surgical debridement of the cornea may be required. The initial presentation of clear vesicles in the skin may not be evident in some cases, and some patients will develop secondary bacterial infections, further confusing clinical analysis.^{130,131} In cases where the etiology is uncertain and local laboratory support is lacking,¹³² a multipronged approach is reasonable, utilizing both antibiotics and antiviral agents. Impetiginized herpes simplex is not uncommon (Figure 5). *Candida* species may sometimes complicate the picture further and should be kept in consideration for immunocompromised patients and those not responding to treatment with antiviral agents and antibiotics alone.¹³³

Rarely, patients may present with multiple red, tender lumps along with signs and symptoms of infection. True granulomatous inflammation may also be present in multiple, simultaneous sites of involvement since it is a systemic response (see below). If a single facial abscess occurs, it would be reasonable to assume that contamination through the skin occurred during treatment. However, if a patient presents with multiple abscesses, it is reasonable to assume that contamination occurred in the syringe prior to injection. Unfortunately, mixing or reformulating products in less-than-ideal conditions is a common occurrence in clinics. Dramatic complications due to microbial contamination of the material may result from these unfortunate instances (Figure 6). Abscesses should not be treated with antibiotics alone, although they may be treated with incision and drainage alone in the absence of surrounding cellulitis.

Hyaluronidase should not be used in the primary phase of treatment, due to the risk of spreading the infected

material diffusely into the tissues if active cellulitis is present. Many bacteria (eg, staphylococci, streptococci, and anaerobes) naturally produce HYAL, which plays a role in their pathogenicity and allows them to spread quickly through the subcutaneous tissues, consuming hyaluronan as they go. The infection should first be controlled with incision and drainage, followed by HYAL if necessary. The author recently treated a patient who presented with recurrent ipsilateral cheek abscess formation on 3 separate occasions despite thorough incision, drainage, and courses of culture-appropriate oral antibiotics. Each of these treatments was apparently successful, but the condition continued to recur after a few weeks. After she was treated with HYAL, no further infection recurred.

Biofilms

Biofilms have been implicated in the development of some filler complications.^{34,36,38,39,99,134} Because bacteria can safely hide from immune defenses when ensconced in their biofilm fortress, antibiotics cannot reach them. As a result, when conditions are favorable, the bacteria can emerge from their planktonic state and reestablish active infection.^{38,135,136} Some bacteria secrete a self-made extracellular polymeric substance—a highly protective “slime layer”¹³⁷—that acts as a form of armor, blocking out the local environment to the point that antimicrobial drugs are no longer effective.^{138,139} Any type of implant, including all fillers, significantly reduces the threshold at which contaminating bacteria can cause infection.^{140,141} Once a biofilm has developed, the bacteria have a “safe room,”¹⁴²

and neither the immune system nor drugs or medication can penetrate the protective layer.¹⁴⁰ Thus, bacteria can lie dormant for very long periods, only to reawaken and cause more problems once the environment is favorable again. When they do arise from their planktonic state, they can cause granulomatous inflammation, abscesses, nodules, and even full-blown recurrent infection.³⁸ Until the foreign body is completely removed, it is difficult if not impossible to remove the biofilm; the bacteria are irreversibly bound to the foreign material. Furthermore, inflammation may be reactivated by punctures of repeated injections.¹⁴³ With solid implants, such as hip or knee joint prostheses, it is impossible to completely clean the devices *ex vivo*, and they must be replaced.^{144,145} New strategies for addressing this issue in solid implants include drug-eluting implant coatings,¹⁴⁶ and future permanent fillers may utilize this strategy. With permanent fillers (eg, PMMA), excision may be the only recourse available. If permanent implants are used in vital structures such as the lips or eyelids, clinical options are limited and difficult choices must be made (Figure 4). The clinician should consider these issues carefully when selecting between permanent or long-lasting fillers in such critical structures. The simplicity of being able to remove HA fillers with HYAL is a very strong benefit.

To date, it has not been conclusively proven that biofilms are involved in granuloma formation, but several recent studies present arguments in favor of this hypothesis.[†] One of these has reported detection of bacteria in culture-negative filler lesions.³⁷ Considering that these fillers are analogous to permanent implants, one wonders at the often lackadaisical manner in which they are commonly demonstrated at clinical teaching symposia, sometimes in unsanitary locations such as hotel rooms and auditoriums. Skin preparation prior to injection should follow standard procedure, which has reduced iatrogenic infection for more than 150 years.¹⁵⁰ Although no evidence-based studies exist on the correct choice for skin preparation prior to dermal filler injection, it seems prudent to follow guidelines for reduction of health care–associated infection.¹⁵¹⁻¹⁵³ These reports recommend the application of 2% chlorhexidine gluconate in 70% alcohol as skin preparation prior to insertion of venous catheters.¹⁵⁴ Disposable sterile dressing trays with containers for prep solution, gauze, and disposable sterile drapes are convenient and inexpensive, and they provide a safe, clean work area in an office setting. To date, there is no proof that a simple alcohol swab prep and the use of nonsterile gloves is insufficient in preventing granulomas or filler infections, but the author believes that transferring surgical expertise in sterile technique to the clinic treatment room may further reduce the prevalence of these complications.

An important distinction between nodules and granulomas is that the former is descriptive; it is the correct term whenever a pathological diagnosis is not available. The latter term should only be used when pathological speci-

mens have been obtained and the required pathological criteria for granulomas have been satisfied—typically described in pathology textbooks as clumps of plump macrophages with hematoxylin-stained nuclei, multinucleated giant cells, and sometimes peripheral lymphocytes. Too often, clinicians refer to all nodules as “granulomas” when no histological pathology has been performed. This is an error that results in sloppy planning and treatment. A nodule should not be diagnosed as a granuloma until it has been confirmed as such.

Immune-Mediated (Noninfectious)

When considering the causes of inflammation apart from infection, product sensitivity and immune-mediated inflammation are of particular importance.^{20,38,101,106,155-158} When Restylane was first formulated, its manufacturer was producing a raw substrate procured from a biologics company that turned out to have an unacceptably high impurity rate. As a result, a moderate number of patients had various inflammatory complications following filler treatment. The company subsequently sourced higher-purity raw materials and significantly reformulated its product. This all occurred prior to FDA approval studies conducted in the United States. The literature is replete with similar stories involving other fillers, many of which moved from country to country, changing names each time to counter reports of AE occurring with earlier formulations. For example, Artefill (Suneva Medical, Inc, San Diego, California) went through several name and formulation changes prior to being approved in the United States. Similar stories can be found with many other products that originated in Eastern European and Asian countries. Somehow, these companies were able to create “clean slates” each time, renaming and tweaking their products as they sought new markets for approval.

As mentioned earlier, sometimes patients are unaware of the nature of the product with which they have been injected. Many patients also forget that they received a specific filler. Therefore, it is important, when possible, to obtain a tissue diagnosis of the problem area. Often, these diagnoses surprise both surgeons and patients, some of whom were not told that they had been injected with silicone, PMMA, or other fillers. Unfortunately, some physicians go as far as to falsify their medical records, and patients in search of a “good deal” are sometimes treated by unlicensed practitioners and are injected with illegal substances such as bathtub caulk, as reported in a recently publicized case that resulted in death.¹⁵⁹⁻¹⁶¹

A large number of publications report granulomatous inflammation involving almost every kind of filler available.[§] There appears to be little consistency in the actual definition of *granuloma* in these case reports; some

[†]References 34, 36-39, 99, 134, 147-149.

[§]References 12, 13, 15, 25, 30-36, 38, 39, 41, 95, 96, 100, 102, 104-108, 110, 113, 117, 119, 120, 123, 124, 127, 128, 158, 162-236.

authors seem to call every solitary nodule a *granuloma*, whereas others use *polymorphonuclear foreign body type giant cells*. The pathology of single nodules is different from that of true granulomatous inflammation, which is a systemic response (type IV hypersensitivity reaction). In a true granulomatous process, all sites that were originally injected with filler material appear adversely affected at the same time. If 4 sites on the patient were injected, then all 4 sites typically are involved at presentation. Solitary nodules have multiple possible causes, and if only 1 of several injected sites is affected, one of the alternative explanations should be considered. In other words, this appears to be a systemic process. Thus, it is likely an error in most cases to call a solitary nodule a “granulomatous lesion” because it is not typically pathologically verified as granulomatous inflammation.

The treatment of granulomatous inflammation should begin with an investigation of what agents have been injected. From there, the physician must decide the best pathway to success. Unfortunately, removal of the product that has been diffusely injected into vital structures such as the lips is neither practical nor desirable. The options, then, consist of methods to control the inflammation and halt the process. Once the diagnosis of granulomatous inflammation has been made as a result of treatment history, physical and, if possible, tissue biopsy, options for treatment are serial injection with cortisone or trials with various drugs. The author has found some success in treatment of these lesions with graduated injections of triamcinolone acetonide, starting with intralesional injections of 0.1 mL of a 10-mg/mL solution and then increasing the concentration to 20 mg/mL and 40 mg/mL with repeated injections until effective. Treatment should occur approximately every 4 weeks, and the amount injected should be carefully controlled to prevent posttreatment soft tissue atrophy. Another possible remedy may be 5-fluorouracil,^{32,148} but the author has used this only once and is therefore not qualified to discuss its proper administration. The multitude of warnings on the label, as well as the requirement for safe use and disposal of 5-fluorouracil products, may also discourage others from utilizing it as a first-line choice.

CONCLUSIONS

In this article, common technical errors in the use of dermal fillers and typical inflammatory complications (both immune and those caused by infectious agents) were reviewed. The prevalence of these complications tends to decrease as clinical experience accumulates. Hyaluronic acid dermal fillers have the advantage of being easily treatable with HYAL, which clinicians are encouraged to have readily available. Reversible filler agents have favorable properties in comparison to permanent, irreversible fillers for the treatment of vital facial structures. Avoidance of minor complications after filler procedures can be accomplished with technical “best practices” and detailed anatomical education. Biofilms may play a role in the

development of nodules, but surgical preparation and good sterile technique may reduce the incidence of these complications. Detailed knowledge of tissue planes in the periorbital region will reduce the incidence of accidental retroseptal injection, or injection anterior to the orbitomalar septum (which causes premalar edema). Importantly, being prepared for emergencies should reduce the severity of adverse outcomes due to improper injection of HA and other filler products.

Disclosures

The author is a medical director, paid consultant, and a member of the speakers bureau for Merz Pharma Canada Inc (Burlington, Ontario), Allergan Canada Inc (Markham, Ontario), Medicis Aesthetics Canada Ltd (Toronto, Ontario), Ethicon Endo-Surgery Inc (Cincinnati, Ohio), and Baxter International Inc (Deerfield, Illinois).

Funding

The author received no financial support for the research, authorship, and publication of this article.

REFERENCES

1. Meyer K, Palmer JW. The polysaccharide of the vitreous humour. *J Biol Chem*. 1934;107:629-634.
2. Garg HG, Hales CA. *Chemistry and Biology of Hyaluronan*. Amsterdam: Elsevier; 2004.
3. Nusgens BV. [Hyaluronic acid and extracellular matrix: a primitive molecule? [in French]. *Ann Dermatol Venereol*. 2010;137(suppl 1):S3-S8.
4. Ascher B, Cerceau M, Baspeyras M, et al. Soft tissue filling with hyaluronic acid [in French]. *Ann Chir Plast Esthet*. 2004;49:465-485.
5. Fraser JR, Laurent TC, Laurent UB. Hyaluronan: its nature, distribution, functions and turnover. *J Intern Med*. 1997;242:27-33.
6. Fraser JR, Dahl LB, Kimpton WG, et al. Elimination and subsequent metabolism of circulating hyaluronic acid in the fetus. *J Dev Physiol*. 1989;11:235-242.
7. Fraser JR, Laurent TC. Turnover and metabolism of hyaluronan. *Ciba Found Symp*. 1989;143:41-53; discussion 53-59, 281-285.
8. Laurent TC. Biochemistry of hyaluronan. *Acta Otolaryngol Suppl*. 1987;442:7-24.
9. Laurent TC, Dahl IM, Dahl LB, et al. The catabolic fate of hyaluronic acid. *Connect Tissue Res*. 1986;15:33-41.
10. Fraser JR, Laurent TC, Engstrom-Laurent A, et al. Elimination of hyaluronic acid from the blood stream in the human. *Clin Exp Pharmacol Physiol*. 1984;11:17-25.
11. Tezel A, Fredrickson GH. The science of hyaluronic acid dermal fillers. *J Cosmet Laser Ther*. 2008;10:35-42.
12. Lowe NJ, Maxwell CA, Patnaik R. Adverse reactions to dermal fillers: review. *Dermatol Surg*. 2005;31:1616-1625.
13. Curcio NM, Parish LC. Injectable fillers: an American perspective. *G Ital Dermatol Venereol*. 2009;144:271-279.
14. Ellis DA, Segall L. Review of non-FDA-approved fillers. *Facial Plast Surg Clin North Am*. 2007;15:239-246, vii.

15. Kontis TC, Rivkin A. The history of injectable facial fillers. *Facial Plast Surg.* 2009;25:67-72.
16. Wesley NO, Dover JS. The filler revolution: a six-year retrospective. *J Drugs Dermatol.* 2009;8:903-907.
17. Rivkin A. New fillers under consideration: what is the future of injectable aesthetics? *Facial Plast Surg.* 2009;25:120-123.
18. Goldberg DJ. Breakthroughs in US dermal fillers for facial soft-tissue augmentation. *J Cosmet Laser Ther.* 2009;11:240-247.
19. Smith KC. Reversible vs. nonreversible fillers in facial aesthetics: concerns and considerations. *Dermatol Online J.* 2008;14:3.
20. Park TH, Seo SW, Kim JK, et al. Clinical experience with hyaluronic acid-filler complications. *J Plast Reconstr Aesthetic Surg.* 2011;64:892-896.
21. Menon H, Thomas M, D'Silva J. Low dose of hyaluronidase to treat over correction by HA filler—a case report. *J Plast Reconstr Aesthetic Surg.* 2010;63:e416-e417.
22. Rzany B, Becker-Wegerich P, Bachmann F, et al. Hyaluronidase in the correction of hyaluronic acid-based fillers: a review and a recommendation for use. *J Cosmet Dermatol.* 2009;8:317-323.
23. Hirsch RJ, Brody HJ, Carruthers JD. Hyaluronidase in the office: a necessity for every dermasurgeon that injects hyaluronic acid. *J Cosmet Laser Ther.* 2007;9:182-185.
24. Pierre A, Levy PM. Hyaluronidase offers an efficacious treatment for inaeesthetic hyaluronic acid overcorrection. *J Cosmet Dermatol.* 2007;6:159-162.
25. Brody HJ. Use of hyaluronidase in the treatment of granulomatous hyaluronic acid reactions or unwanted hyaluronic acid misplacement. *Dermatol Surg.* 2005;31:893-897.
26. Lambros V. The use of hyaluronidase to reverse the effects of hyaluronic acid filler. *Plast Reconstr Surg.* 2004;114:277.
27. Soparkar CN, Patrinely JR, Tschen J. Erasing Restylane. *Ophthalm Plast Reconstr Surg.* 2004;20:317-318.
28. Park TH, Seo SW, Kim JK, et al. Clinical outcome in a series of 173 cases of foreign body granuloma: improved outcomes with a novel surgical technique. *J Plast Reconstr Aesthetic Surg.* 2012;65:29-34.
29. Park TH, Seo SW, Kim JK, et al. Clinical experience with polymethylmethacrylate microsphere filler complications. *Aesthetic Plast Surg.* 2012;36:421-426.
30. Lemperle G, Gauthier-Hazan N. Foreign body granulomas after all injectable dermal fillers: part 2. Treatment options. *Plast Reconstr Surg.* 2009;123:1864-1873.
31. Stewart DB, Morganroth GS, Mooney MA, et al. Management of visible granulomas following periorbital injection of poly-L-lactic acid. *Ophthalm Plast Reconstr Surg.* 2007;23:298-301.
32. Lemperle G, Rullan PP, Gauthier-Hazan N. Avoiding and treating dermal filler complications. *Plast Reconstr Surg.* 2006;118:92S-107S.
33. Nicolau PJ. Long-lasting and permanent fillers: biomaterial influence over host tissue response. *Plast Reconstr Surg.* 2007;119:2271-2286.
34. Rohrich RJ, Monheit G, Nguyen AT, et al. Soft-tissue filler complications: the important role of biofilms. *Plast Reconstr Surg.* 2010;125:1250-1256.
35. Narins RS, Coleman WP III, Glogau RG. Recommendations and treatment options for nodules and other filler complications. *Dermatol Surg.* 2009;35(suppl 2):1667-1671.
36. Christensen LH. Host tissue interaction, fate, and risks of degradable and nondegradable gel fillers. *Dermatol Surg.* 2009;35(suppl 2):1612-1619.
37. Bjarnsholt T, Tolker-Nielsen T, Givskov M, et al. Detection of bacteria by fluorescence in situ hybridization in culture-negative soft tissue filler lesions. *Dermatol Surg.* 2009;35(suppl 2):1620-1624.
38. Bentkover SH. The biology of facial fillers. *Facial Plast Surg.* 2009;25:73-85.
39. Christensen L. Normal and pathologic tissue reactions to soft tissue gel fillers. *Dermatol Surg.* 2007;33(suppl 2):S168-S175.
40. Bachmann F, Erdmann R, Hartmann V, et al. Adverse reactions caused by consecutive injections of different fillers in the same facial region: risk assessment based on the results from the Injectable Filler Safety study. *J Eur Acad Dermatol Venereol.* 2011;25:902-912.
41. Lemperle G, Hazan-Gauthier N, Lemperle M. PMMA microspheres (Artecoll) for skin and soft-tissue augmentation, part II: clinical investigations. *Plast Reconstr Surg.* 1995;96:627-634.
42. Laeschke K. Biocompatibility of microparticles into soft tissue fillers. *Semin Cutan Med Surg.* 2004;23:214-217.
43. Meyer K. The biological significance of hyaluronic acid and hyaluronidase. *Physiol Rev.* 1947;27:335-359.
44. Atkinson WS. Use of hyaluronidase with local anesthesia in ophthalmology: preliminary report. *Arch Ophthalmol.* 1949;42:628-633.
45. Hechter O, Dopkeen SK, Yudell MH. The clinical use of hyaluronidase in hypodermoclysis. *J Pediatr.* 1947;30:645-656.
46. Greenberg BE, Gargill SL. The relation of hyaluronidase in the seminal fluid to fertility. *Hum Fertil.* 1946;11:1.
47. Kurzrok R. Hyaluronidase; an enzyme essential for human fertility. *Manitoba Med Rev.* 1948;28:216.
48. Riisfeldt O. Studies on hyaluronidase in semen from men in sterile and fertile marriages. *Ann Ostet Gynecol.* 1951;73:853-871.
49. Jadin L, Bookbinder LH, Frost GI. A comprehensive model of hyaluronan turnover in the mouse. *Matrix Biol.* 2012;31:81-89.
50. Hofinger ES, Hoechstetter J, Oetl M, et al. Isoenzyme-specific differences in the degradation of hyaluronic acid by mammalian-type hyaluronidases. *Glycoconj J.* 2008;25:101-109.
51. Delaere L, Zeyen T, Foets B, et al. Allergic reaction to hyaluronidase after retrobulbar anaesthesia: a case series and review. *Int Ophthalmol.* 2009;29:521-528.
52. Leibovitch I, Tamblyn D, Casson R, et al. Allergic reaction to hyaluronidase: a rare cause of orbital inflammation after cataract surgery. *Graefes Arch Clin Exp Ophthalmol.* 2006;244:944-949.
53. Patil B, Agius-Fernandez A, Worstmann T. Hyaluronidase allergy after peribulbar anesthesia with orbital inflammation. *J Cataract Refract Surg.* 2005;31:1480-1481.
54. Escolano F, Pares N, Gonzalez I, et al. Allergic reaction to hyaluronidase in cataract surgery. *Eur J Anaesthesiol.* 2005;22:729-730.

55. Quhill F, Bowling B, Packard RB. Hyaluronidase allergy after peribulbar anesthesia with orbital inflammation. *J Cataract Refract Surg.* 2004;30:916-917.
56. Eberhart AH, Weiler CR, Erie JC. Angioedema related to the use of hyaluronidase in cataract surgery. *Am J Ophthalmol.* 2004;138:142-143.
57. Nicholson G, Hall GM. Allergic reaction to hyaluronidase after a peribulbar injection. *Anaesthesia.* 2003;58:814-815.
58. Ahluwalia HS, Lukaris A, Lane CM. Delayed allergic reaction to hyaluronidase: a rare sequel to cataract surgery. *Eye.* 2003;17:263-266.
59. Agrawal A, McLure HA, Dabbs TR. Allergic reaction to hyaluronidase after a peribulbar injection. *Anaesthesia.* 2003;58:493-494.
60. Kirby B, Butt A, Morrison AM, et al. Type I allergic reaction to hyaluronidase during ophthalmic surgery. *Contact Dermatitis.* 2001;44:52.
61. Minning CA Jr. Hyaluronidase allergy simulating expulsive choroidal hemorrhage. *Arch Ophthalmol.* 1994;112:585-586.
62. Sakamoto K, Nagai H, Koda A. Role of hyaluronidase in immediate hypersensitivity reaction. *Immunopharmacology.* 1980;2:139-146.
63. Richter G, Richter W. The risk of intravenous treatment with hyaluronidase from a dermatological viewpoint [in German]. *Dermatol Monatschr.* 1975;161:952-955.
64. McEwen LM, Starr MS. Enzyme-potentiated hyposensitization, I: the effect of pre-treatment with -glucuronidase, hyaluronidase, and antigen on anaphylactic sensitivity of guinea-pigs, rats and mice. *Int Arch Allergy Appl Immunol.* 1972;42:152-158.
65. Kind LS, Roffler S. Allergic reactions to hyaluronidase. *Proc Soc Exp Biol Med.* 1961;106:734-735.
66. Ebo DG, Goossens S, Opsomer F, et al. Flow-assisted diagnosis of anaphylaxis to hyaluronidase. *Allergy.* 2005;60:1333-1334.
67. Muller U, Bircher A, Bischof M. Allergic angioedema after local dental anesthesia and a hyaluronidase-containing preanesthetic injection solution [in German]. *Schweiz Med Wochenschr.* 1986;116:1810-1813.
68. Lee HK, Choi EJ, Lee PB, et al. Anaphylactic shock caused by the epidurally-administered hyaluronidase. *Korean J Pain.* 2011;24:221-225.
69. Morley AM, Malhotra R. Use of hyaluronic acid filler for tear-trough rejuvenation as an alternative to lower eyelid surgery. *Ophthalm Plast Reconstr Surg.* 2011;27:69-73.
70. Van Dyke S, Hays GP, Caglia AE, et al. Severe acute local reactions to a hyaluronic acid-derived dermal filler. *J Clin Aesthetic Dermatol.* 2010;3:32-35.
71. Skeie L, Bugge H, Negaard A, et al. Large particle hyaluronic acid for the treatment of facial lipoatrophy in HIV-positive patients: 3-year follow-up study. *HIV Med.* 2010;11:170-177.
72. Menon H, Thomas M, D'Silva J. Low dose of hyaluronidase to treat over correction by HA filler—a case report. *J Plast Reconstr Aesthetic Surg.* 2010;63:e416-e417.
73. Volpi N, Schiller J, Stern R, et al. Role, metabolism, chemical modifications and applications of hyaluronan. *Curr Med Chem.* 2009;16:1718-1745.
74. Sclafani AP, Fagien S. Treatment of injectable soft tissue filler complications. *Dermatol Surg.* 2009;35(suppl 2):1672-1680.
75. Grunebaum LD, Bogdan Allemann I, Dayan S, et al. The risk of alar necrosis associated with dermal filler injection. *Dermatol Surg.* 2009;35(suppl 2):1635-1640.
76. Goldman MP. Pressure-induced migration of a permanent soft tissue filler. *Dermatol Surg.* 2009;35(suppl 1):403-405; discussion 405-406.
77. Cox SE. Clinical experience with filler complications. *Dermatol Surg.* 2009;35(suppl 2):1661-1666.
78. Hirsch RJ, Brody HJ, Carruthers JD. Hyaluronidase in the office: a necessity for every dermasurgeon that injects hyaluronic acid. *J Cosmet Laser Ther.* 2007;9:182-185.
79. Goldberg RA, Fiaschetti D. Filling the periorbital hollows with hyaluronic acid gel: initial experience with 244 injections. *Ophthalm Plast Reconstr Surg.* 2006;22:335-341; discussion 341-343.
80. Glaich AS, Cohen JL, Goldberg LH. Injection necrosis of the glabella: protocol for prevention and treatment after use of dermal fillers. *Dermatol Surg.* 2006;32:276-281.
81. Hirsch RJ, Carruthers JD, Carruthers A. Infraorbital hollow treatment by dermal fillers. *Dermatol Surg.* 2007;33:1116-1119.
82. Morris CL, Stinnett SS, Woodward JA. Patient-preferred sites of Restylane injection in periocular and facial soft-tissue augmentation. *Ophthalm Plast Reconstr Surg.* 2008;24:117-121.
83. Pessa JE, Zadoo VP, Adrian EK, et al. Anatomy of a "black eye": a newly described fascial system of the lower eyelid. *Clin Anat.* 1998;11:157-161.
84. Pessa JE, Garza JR. The malar septum: the anatomic basis of malar mounds and malar edema. *Aesthetic Surg J.* 1997;17:11-17.
85. Funt DK. Avoiding malar edema during midface/cheek augmentation with dermal fillers. *J Clin Aesthetic Dermatol.* 2011;4:32-36.
86. Zhang H, Liu C, Peng C, et al. Blending of the eyelid-cheek junction and removal of protruding fat: an intraoral approach to blepharoplasty of the lower eyelid. *Br J Oral Maxillofac Surg.* 2009;47:541-544.
87. Hwang SH, Hwang K, Jin S, et al. Location and nature of retro-orbicularis oculi fat and suborbicularis oculi fat. *J Craniofac Surg.* 2007;18:387-390.
88. Yousif NJ, Sonderman P, Dzwierzynski WW, et al. Anatomic considerations in transconjunctival blepharoplasty. *Plast Reconstr Surg.* 1995;96:1271-1276; discussion 1277-1278.
89. Ilankovan V. Transconjunctival approach to the infraorbital region: a cadaveric and clinical study. *Br J Oral Maxillofac Surg.* 1991;29:169-172.
90. Laurent TC, Fraser JR. Hyaluronan. *Faseb J.* 1992;6:2397-2404.
91. Brandt FS, Cazzaniga A. Hyaluronic acid gel fillers in the management of facial aging. *Clin Interv Aging.* 2008;3:153-159.
92. Douse-Dean T, Jacob CI. Fast and easy treatment for reduction of the Tyndall effect secondary to cosmetic use of hyaluronic acid. *J Drugs Dermatol.* 2008;7:281-283.

93. Fezza JP. Nonsurgical treatment of cicatricial ectropion with hyaluronic acid filler. *Plast Reconstr Surg.* 2008;121:1009-1014.
94. Hirsch RJ, Narurkar V, Carruthers J. Management of injected hyaluronic acid induced Tyndall effects. *Lasers Surg Med.* 2006;38:202-204.
95. Alijotas-Reig J, Garcia-Gimenez V. Delayed immune-mediated adverse effects related to hyaluronic acid and acrylic hydrogel dermal fillers: clinical findings, long-term follow-up and review of the literature. *J Eur Acad Dermatol Venereol.* 2008;22:150-161.
96. Bachmann F, Erdmann R, Hartmann V, et al. The spectrum of adverse reactions after treatment with injectable fillers in the glabellar region: results from the Injectable Filler Safety Study. *Dermatol Surg.* 2009;35(suppl 2):1629-1634.
97. Bergeret-Galley C, Latouche X, Illouz YG. The value of a new filler material in corrective and cosmetic surgery: DermaLive and DermaDeep. *Aesthetic Plast Surg.* 2001;25:249-255.
98. Braun M, Braun S. Nodule formation following lip augmentation using porcine collagen-derived filler. *J Drugs Dermatol.* 2008;7:579-581.
99. Christensen L, Breiting V, Janssen M, et al. Adverse reactions to injectable soft tissue permanent fillers. *Aesthetic Plast Surg.* 2005;29:34-48.
100. Massone C, Horn M, Kerl H, et al. Foreign body granuloma due to Matridex injection for cosmetic purposes. *Am J Dermatopathol.* 2009;31:197-199.
101. Rossner M, Rossner F, Bachmann F, et al. Risk of severe adverse reactions to an injectable filler based on a fixed combination of hydroxyethylmethacrylate and ethylmethacrylate with hyaluronic acid. *Dermatol Surg.* 2009;35(suppl 1):367-374.
102. Wiest LG, Stolz W, Schroeder JA. Electron microscopic documentation of late changes in permanent fillers and clinical management of granulomas in affected patients. *Dermatol Surg.* 2009;35(suppl 2):1681-1688.
103. Zielke H, Wolber L, Wiest L, et al. Risk profiles of different injectable fillers: results from the Injectable Filler Safety Study (IFS Study). *Dermatol Surg.* 2008;34:326-335; discussion 335.
104. Alam M, Yoo SS. Technique for calcium hydroxylapatite injection for correction of nasolabial fold depressions. *J Am Acad Dermatol.* 2007;56:285-289.
105. Alcalay J, Alcalay R, Gat A, et al. Late-onset granulomatous reaction to Artecoll. *Dermatol Surg.* 2003;29:859-862.
106. Alijotas-Reig J, Garcia-Gimenez V, Miro-Mur F, et al. Delayed immune-mediated adverse effects of polyalkylimide dermal fillers: clinical findings and long-term follow-up. *Arch Dermatol.* 2008;144:637-642.
107. Alijotas-Reig J, Garcia-Gimenez V, Miro-Mur F, et al. Delayed immune-mediated adverse effects related to polyacrylamide dermal fillers: clinical findings, management, and follow-up. *Dermatol Surg.* 2009;35(suppl 1):360-366.
108. Alijotas-Reig J, Garcia-Gimenez V, Vilardell-Tarres M. Late-onset immune-mediated adverse effects after poly-L-lactic acid injection in non-HIV patients: clinical findings and long-term follow-up. *Dermatology.* 2009;219:303-308.
109. Amin SP, Marmur ES, Goldberg DJ. Complications from injectable polyacrylamide gel, a new nonbiodegradable soft tissue filler. *Dermatol Surg.* 2004;30:1507-1509.
110. Anwar MU, Sharpe DT. Skin nodules after semipermanent cosmetic dermal filler. *Aesthetic Plast Surg.* 2007;31:401-402.
111. Bass LS, Smith S, Busso M, et al. Calcium hydroxylapatite (Radiesse) for treatment of nasolabial folds: long-term safety and efficacy results. *Aesthetic Surg J.* 2010;30:235-238.
112. Belmontesi M, Grover R, Verpaele A. Transdermal injection of Restylane SubQ for aesthetic contouring of the cheeks, chin, and mandible. *Aesthetic Surgery J.* 2006;26:S28-S34.
113. Burgess CM, Quiroga RM. Assessment of the safety and efficacy of poly-L-lactic acid for the treatment of HIV-associated facial lipoatrophy. *J Am Acad Dermatol.* 2005;52:233-239.
114. Cosatti M, Fernandez Romero DS, Juri MC, et al. Facial angioedema after filler injections: description of five cases [in Spanish]. *Medicina.* 2010;70:513-517.
115. Heinz BC, Ladhoff U, Kahl C, et al. Survey of incidents associated with injectable dermal fillers reported to the German Medical Devices Vigilance System [in German]. *Bundesgesundheitsblatt Gesundheitsforschung Gesundheitsschutz.* 2008;51:787-792.
116. Jansen DA, Graivier MH. Evaluation of a calcium hydroxylapatite-based implant (Radiesse) for facial soft-tissue augmentation. *Plast Reconstr Surg.* 2006;118:22S-30S, discussion 31S-33S.
117. Lemperle G, Gauthier-Hazan N, Wolters M. [Complications after dermal fillers and their treatment [in German]]. *Handchir Mikrochir Plast Chir.* 2006;38:354-369.
118. Moscona RA, Fodor L. A retrospective study on liquid injectable silicone for lip augmentation: long-term results and patient satisfaction. *J Plast Reconstr Aesthetic Surg.* 2010;63:1694-1698.
119. Narins RS. Minimizing adverse events associated with poly-L-lactic acid injection. *Dermatol Surg.* 2008;34(suppl 1):S100-S104.
120. Ross AH, Malhotra R. Long-term orbitofacial complications of polyalkylimide 4% (bio-alcamid). *Ophthal Plast Reconstr Surg.* 2009;25:394-397.
121. Rossner F, Rossner M, Hartmann V, et al. Decrease of reported adverse events to injectable polylactic acid after recommending an increased dilution: 8-year results from the Injectable Filler Safety study. *J Cosmet Dermatol.* 2009;8:14-18.
122. Sadick NS, Katz BE, Roy D. A multicenter, 47-month study of safety and efficacy of calcium hydroxylapatite for soft tissue augmentation of nasolabial folds and other areas of the face. *Dermatol Surg.* 2007;33(suppl 2):S122-126; discussion S126-S127.
123. Schwartzfarb EM, Hametti JM, Romanelli P, et al. Foreign body granuloma formation secondary to silicone injection. *Dermatol Online J.* 2008;14:20.
124. Thyssen JP, Christensen LH, Zachariae CO. Cosmetic soft-tissue augmentation treatment [in Danish]. *Ugesk Laeger.* 2007;169:2198-2201.
125. Tzikas TL. Evaluation of the Radiance FN soft tissue filler for facial soft tissue augmentation. *Arch Facial Plast Surg.* 2004;6:234-239.

126. Wang YB, Huang JJ, Qiao Q, et al. Clinically analyzing the possible side-effects after injecting hydrophilic polyacrylamide gel as a soft-tissue filler in Chinese]. *Zhonghua Zheng Xing Wai Ke Za Zhi*. 2003;19:328-330.
127. Wiest LG. History and use of fillers for treating wrinkles [in German]. *Hautarzt*. 2007;58:224-231.
128. Cassuto D, Marangoni O, De Santis G, et al. Advanced laser techniques for filler-induced complications. *Dermatol Surg*. 2009;35(suppl 2):1689-1695.
129. Cohen JL. Understanding, avoiding, and managing dermal filler complications. *Dermatol Surg*. 2008;34(suppl 1):S92-S99.
130. Laube S. Skin infections and ageing. *Ageing Res Rev*. 2004;3:69-89.
131. Diaz LA, Giudice GJ. End of the century overview of skin blisters. *Arch Dermatol*. 2000;136:106-112.
132. Oranje AP, Folkers E, Choufoer-Habova J, et al. Diagnostic value of Tzanck smear in herpetic and non-herpetic vesicular and bullous skin disorders in pediatric practice. *Acta Derm Venereol*. 1986;66:127-133.
133. Klastersky J. Infections in immunocompromised patients, I: pathogenesis, etiology, and diagnosis. *Clin Ther*. 1985;8:90-99.
134. Sadashivaiah AB, Mysore V. Biofilms: their role in dermal fillers. *J Cutan Aesthetic Surg*. 2010;3:20-22.
135. Wilson M. Bacterial biofilms and human disease. *Sci Progress*. 2001;84:235-254.
136. Costerton JW, Montanaro L, Arciola CR. Biofilm in implant infections: its production and regulation. *Int J Artif Organs*. 2005;28:1062-1068.
137. Wadstrom T. Molecular aspects of bacterial adhesion, colonization, and development of infections associated with biomaterials. *J Invest Surg*. 1989;2:353-360.
138. Ramage G, Culshaw S, Jones B, et al. Are we any closer to beating the biofilm: novel methods of biofilm control. *Curr Opin Infect Dis*. 2010;23:560-566.
139. McCann MT, Gilmore BF, Gorman SP. *Staphylococcus epidermidis* device-related infections: pathogenesis and clinical management. *J Pharm Pharmacol*. 2008;60:1551-1571.
140. Uckay I, Pittet D, Vaudaux P, et al. Foreign body infections due to *Staphylococcus epidermidis*. *Ann Med*. 2009;41:109-119.
141. Miclau T, Schmidt AH, Wenke JC, et al. Infection. *J Orthop Trauma*. 2010;24:583-586.
142. Rossi C, Thys JP. Prosthesis-related infections [in French]. *Rev Med Brux*. 2000;21:143-148.
143. El-Shafey el SI. Complications from repeated injection or puncture of old polyacrylamide gel implant sites: case reports. *Aesthetic Plast Surg*. 2008;32:162-165.
144. Gallo J, Kolar M, Novotny R, et al. Pathogenesis of prosthesis-related infection. *Biomed Pap Med Fac Univ Palacky Olomouc Czech Repub*. 2003;147:27-35.
145. Costerton JW. Biofilm theory can guide the treatment of device-related orthopaedic infections. *Clin Orthop Relat Res*. 2005;(437):7-11.
146. Winkler H. Rationale for one stage exchange of infected hip replacement using uncemented implants and antibiotic impregnated bone graft. *Int J Med Sci*. 2009;6:247-252.
147. Marusza W, Mlynarczyk G, Olszanski R, et al. Probable biofilm formation in the cheek as a complication of soft tissue filler resulting from improper endodontic treatment of tooth 16. *Int J Nanomed*. 2012;7:1441-1447.
148. Dayan SH, Arkins JP, Brindise R. Soft tissue fillers and biofilms. *Facial Plast Surg*. 2011;27:23-28.
149. Hassid VJ. Soft-tissue filler complications: the important role of biofilms. *Plast Reconstr Surg*. 2010;126:1801-1802; author reply 1802.
150. Crosby CT, Tsj E, Lambert PA, et al. Preoperative skin preparation: a historical perspective. *Br J Hosp Med (Lond)*. 2009;70:579-582.
151. Yokoe DS, Mermel LA, Anderson DJ, et al. A compendium of strategies to prevent healthcare-associated infections in acute care hospitals. *Infect Control Hosp Epidemiol*. 2008;29(suppl 1):S12-S21.
152. Pratt RJ, O'Malley B. Supporting evidence-based infection prevention and control practice in the National Health Service in England. The NHS/TVU/Intuition Approach. *J Hosp Infect*. 2007;65(suppl 2):142-147.
153. Pratt RJ, Pellowe CM, Wilson JA, et al. epic2: national evidence-based guidelines for preventing healthcare-associated infections in NHS hospitals in England. *J Hosp Infect*. 2007;65(suppl 1):S1-S64.
154. Inwood S. Skin antisepsis: using 2% chlorhexidine gluconate in 70% isopropyl alcohol. *Br J Nurs*. 2007;16:1390, 1392-1394.
155. Caldellas AV, de Castro CC, Aboudib JH, et al. The polymethylmethacrylate effects on auricle conchal cartilage: report of 21 cases. *Aesthetic Surg J*. 2010;30:434-438.
156. Fischer J, Metzler G, Schaller M. Cosmetic permanent fillers for soft tissue augmentation: a new contraindication for interferon therapies. *Arch Dermatol*. 2007;143:507-510.
157. Judodihardjo H, Dykes P. Objective and subjective measurements of cutaneous inflammation after a novel hyaluronic acid injection. *Dermatol Surg*. 2008;34(suppl 1):S110-S114.
158. Winslow CP. The management of dermal filler complications. *Facial Plast Surg*. 2009;25:124-128.
159. Childs D. Boosting butts with cement, Fix-A-Flat, leads to arrest. <http://abcnews.go.com/blogs/health/2011/11/18/man-arrested-for-boosting-butts-with-cement-fix-a-flat/>. Accessed March 25, 2013.
160. Crimesider staff alleged "Fix-a-Flat" fake surgeon Oneal Ron Morris arrested again after more victims come forward. http://www.cbsnews.com/8301-504083_162-57397200-504083/alleged-fix-a-flat-fake-surgeon-oneal-ron-morris-arrested-again-after-more-vic-tims-come-forward/. Accessed March 25, 2013.
161. Florida Department of Health Press Release. Florida Department of Health's joint efforts result in felony arrest-partnered investigation highlights department's unlicensed activity unit, July 27, 2012. <http://newsroom.doh.state.fl.us/wp-content/uploads/newsroom/2011/08/72712Brwr.pdf>. Accessed March 25, 2013.
162. Sachdev M, Anantheswar Y, Ashok B, et al. Facial granulomas secondary to injection of semi-permanent cosmetic

- dermal filler containing acrylic hydrogel particles. *J Cutan Aesthetic Surg.* 2010;3:162-166.
163. Planas J. The use of Integra in rhinoplasty. *Aesthetic Plast Surg.* 2010;35:5-12.
 164. Manafi A, Emami AH, Pooli AH, et al. Unacceptable results with an accepted soft tissue filler: polyacrylamide hydrogel. *Aesthetic Plast Surg.* 2010;34:413-422.
 165. Sneistrup C, Holmich LR, Dahlstrom K. Long-term complications after injection of permanent tissue-fillers to the lips [in Danish]. *Ugeskr Laeger.* 2009;171:1414.
 166. Shaeer O, Shaeer K. Delayed complications of gel injection for penile girth augmentation. *J Sex Med.* 2009;6:2072-2078.
 167. Sclafani AP, Fagien S. Treatment of injectable soft tissue filler complications. *Dermatol Surg.* 2009;35(suppl 2):1672-1680.
 168. Schelke LW, van den Elzen HJ, Canninga M, et al. Complications after treatment with polyalkylimide. *Dermatol Surg.* 2009;35(suppl 2):1625-1628.
 169. Sanchis-Bielsa JM, Bagan JV, Poveda R, et al. Foreign body granulomatous reactions to cosmetic fillers: a clinical study of 15 cases. *Oral Surg Oral Med Oral Pathol Oral Radiol Endod.* 2009;108:237-241.
 170. Sage RJ, Chaffins ML, Kouba DJ. Granulomatous foreign body reaction to hyaluronic acid: report of a case after melolabial fold augmentation and review of management. *Dermatol Surg.* 2009;35(suppl 2):1696-1700.
 171. Reszko AE, Sadick NS, Magro CM, et al. Late-onset subcutaneous nodules after poly-L-lactic acid injection. *Dermatol Surg.* 2009;35(suppl 1):380-384.
 172. Pons-Guiraud A. Adverse reactions to injectable fillers [in French]. *Ann Dermatol Venereol.* 2009;136(suppl 6):S293-S298.
 173. Monheit GD, Rohrich RJ. The nature of long-term fillers and the risk of complications. *Dermatol Surg.* 2009;35(suppl 2):1598-1604.
 174. Manafi A, Emami AH, Pooli AH, et al. Unacceptable results with an accepted soft tissue filler: polyacrylamide hydrogel. *Aesthetic Plast Surg.* 2010;34:413-422.
 175. Mamelak AJ, Katz TM, Goldberg LH, et al. Foreign body reaction to hyaluronic acid filler injection: in search of an etiology. *Dermatol Surg.* 2009;35(suppl 2):1701-1703.
 176. Lemperle G, Sadick NS, Knapp TR, et al. ArteFill permanent injectable for soft tissue augmentation, II: indications and applications. *Aesthetic Plast Surg.* 2010;34:273-286.
 177. Lemperle G, Gauthier-Hazan N, Wolters M, et al. Foreign body granulomas after all injectable dermal fillers, part 1: possible causes. *Plast Reconstr Surg.* 2009;123:1842-1863.
 178. Humphrey CD, Arkins JP, Dayan SH. Soft tissue fillers in the nose. *Aesthetic Surg J.* 2009;29:477-484.
 179. Furmanczyk PS, Wolgamot GM, Argenyi ZB, et al. Extensive granulomatous reaction occurring 1.5 years after Dermalive injection. *Dermatol Surg.* 2009;35(suppl 1):385-388.
 180. da Costa Miguel MC, Nonaka CF, dos Santos JN, et al. Oral foreign body granuloma: unusual presentation of a rare adverse reaction to permanent injectable cosmetic filler. *Int J Oral Maxillofac Surg.* 2009;38:385-387.
 181. Beer K. Clinicopathologic correlation of delayed-onset periorbital poly-L-lactic acid nodules. *Dermatol Surg.* 2009;35(suppl 1):399-402.
 182. Beer K. Delayed onset nodules from liquid injectable silicone: report of a case, evaluation of associated histopathology and results of treatment with minocycline and celastrol. *J Drugs Dermatol.* 2009;8:952-954.
 183. Altmeyer MD, Anderson LL, Wang AR. Silicone migration and granuloma formation. *J Cosmet Dermatol.* 2009;8:92-97.
 184. Thioly-Bensoussan D. Non-hyaluronic acid fillers. *Clin Dermatol.* 2008;26:160-176.
 185. Salles AG, Lotierzo PH, Gemperli R, et al. Complications after polymethylmethacrylate injections: report of 32 cases. *Plast Reconstr Surg.* 2008;121:1811-1820.
 186. Rongioletti F. Granulomatous reactions from aesthetic dermal micro-implants [in French]. *Ann Dermatol Venereol.* 2008;135:1S59-1S65.
 187. Pons-Guiraud A. Adverse reactions to injectable fillers [in French]. *Ann Dermatol Venereol.* 2008;135(suppl 3):S171-S174.
 188. Hirsch RJ, Stier M. Complications of soft tissue augmentation. *J Drugs Dermatol.* 2008;7:841-845.
 189. Gonzalez-Vela MC, Armesto S, Gonzalez-Lopez MA, et al. Perioral granulomatous reaction to Dermalive. *Dermatol Surg.* 2008;34:986-988.
 190. Fitzgerald R, Vleggaar D, Burgess C. Facial dermal fillers. *Aesthetic Surg J.* 2008;28:699-701; author reply 701.
 191. Dayan SH, Bassichis BA. Facial dermal fillers: selection of appropriate products and techniques. *Aesthetic Surg J.* 2008;28:335-347.
 192. Anastassov GE, Schulhof S, Lumerman H. Complications after facial contour augmentation with injectable silicone: diagnosis and treatment. Report of a severe case. *Int J Oral Maxillofac Surg.* 2008;37:955-960.
 193. Mustacchio V, Cabibi D, Minervini MI, et al. A diagnostic trap for the dermatopathologist: granulomatous reactions from cutaneous microimplants for cosmetic purposes. *J Cutan Pathol.* 2007;34:281-283.
 194. Edwards PC, Fantasia JE. Review of long-term adverse effects associated with the use of chemically-modified animal and nonanimal source hyaluronic acid dermal fillers. *Clin Interv Aging.* 2007;2:509-519.
 195. Chasan PE. The history of injectable silicone fluids for soft-tissue augmentation. *Plast Reconstr Surg.* 2007;120:2034-2040; discussion 2041-2043.
 196. Bardazzi F, Ruffato A, Antonucci A, et al. Cutaneous granulomatous reaction to injectable hyaluronic acid gel: another case. *J Dermatol Treat.* 2007;18:59-62.
 197. Baijens L, Speyer R, Linssen M, et al. Rejection of injectable silicone "Bioplastique" used for vocal fold augmentation. *Eur Arch Otorhinolaryngol.* 2007;264:565-568.
 198. Al-Shraim M, Jaragh M, Geddie W. Granulomatous reaction to injectable hyaluronic acid (Restylane) diagnosed by fine needle biopsy. *J Clin Pathol.* 2007;60:1060-1061.
 199. Wolfram D, Tzankov A, Piza-Katzer H. Surgery for foreign body reactions due to injectable fillers. *Dermatology.* 2006;213:300-304.
 200. Vargas-Machuca I, Gonzalez-Guerra E, Angulo J, et al. Facial granulomas secondary to Dermalive microimplants: report of a case with histopathologic differential

- diagnosis among the granulomas secondary to different injectable permanent filler materials. *Am J Dermatopathol*. 2006;28:173-177.
201. Sidwell RU, McL Johnson N, Francis N, et al. Cutaneous sarcoidal granulomas developing after Artecoll facial cosmetic filler in a patient with newly diagnosed systemic sarcoidosis. *Clin Exp Dermatol*. 2006;31:208-211.
202. Poveda R, Bagan JV, Murillo J, et al. Granulomatous facial reaction to injected cosmetic fillers—a presentation of five cases [in English, Spanish]. *Med Oral Patol Oral Cir Bucal*. 2006;11:E1-E5.
203. Lemperle G, de Fazio S, Nicolau P. ArteFill: a third-generation permanent dermal filler and tissue stimulator. *Clin Plast Surg*. 2006;33:551-565.
204. Kopera D. Permanent filler augmentation: common complications. *Arch Dermatol*. 2006;142:1508.
205. Ghislanzoni M, Bianchi F, Barbareschi M, et al. Cutaneous granulomatous reaction to injectable hyaluronic acid gel. *Br J Dermatol*. 2006;154:755-758.
206. Edwards PC, Fantasia JE, Iovino R. Foreign body reaction to hyaluronic acid (Restylane): an adverse outcome of lip augmentation. *J Oral Maxillofac Surg*. 2006;64:1296-1299; discussion 1299.
207. Coleman SR. Cross-linked hyaluronic acid fillers. *Plast Reconstr Surg*. 2006;117:661-665.
208. Bauer U, Vleggaar D. Response to “New-fill injections may induce late-onset foreign body granulomatous reaction.” *Plast Reconstr Surg*. 2006;118:265; author reply 265-266.
209. Angus JE, Affleck AG, Leach IH, et al. Two cases of delayed granulomatous reactions to the cosmetic filler Dermalive, a hyaluronic acid and acrylic hydrogel. *Br J Dermatol*. 2006;155:1077-1078.
210. Soparkar CN, Patrinely JR. Managing inflammatory reaction to restylane. *Ophthal Plast Reconstr Surg*. 2005;21:151-153.
211. Pinheiro MV, Bagatin E, Hassun KM, et al. Adverse effect of soft tissue augmentation with hyaluronic acid. *J Cosmet Dermatol*. 2005;4:184-186.
212. Parada MB, Michalany NS, Hassun KM, et al. A histologic study of adverse effects of different cosmetic skin fillers. *Skinmed*. 2005;4:345-349.
213. Lloret P, Espana A, Leache A, et al. Successful treatment of granulomatous reactions secondary to injection of esthetic implants. *Dermatol Surg*. 2005;31:486-490.
214. Fulton JE, Jr, Porumb S, Caruso JC, et al. Lip augmentation with liquid silicone. *Dermatol Surg*. 2005;31:1577-1585; discussion 1586.
215. Duffy DM. Complications of fillers: overview. *Dermatol Surg*. 2005;31:1626-1633.
216. Dijkema SJ, van der Lei B, Kibbelaar RE. New-fill injections may induce late-onset foreign body granulomatous reaction. *Plast Reconstr Surg*. 2005;115:76e-78e.
217. Dal Sacco D, Cozzani E, Parodi A, et al. Scar sarcoidosis after hyaluronic acid injection. *Int J Dermatol*. 2005;44:411-412.
218. Carruthers A, Carruthers JD. Polymethylmethacrylate microspheres/collagen as a tissue augmenting agent: personal experience over 5 years. *Dermatol Surg*. 2005;31:1561-1564; discussion 1565.
219. Beljaards RC, de Roos KP, Bruins FG. NewFill for skin augmentation: a new filler or failure? *Dermatol Surg*. 2005;31:772-776; discussion 776.
220. Andre P, Lowe NJ, Parc A, et al. Adverse reactions to dermal fillers: a review of European experiences. *J Cosmet Laser Ther*. 2005;7:171-176.
221. Zimmermann US, Clerici TJ. The histological aspects of fillers complications. *Semin Cutan Med Surg*. 2004;23:241-250.
222. Vochelle D. The use of poly-L-lactic acid in the management of soft-tissue augmentation: a five-year experience. *Semin Cutan Med Surg*. 2004;23:223-226.
223. Sidwell RU, Dhillon AP, Butler PE, et al. Localized granulomatous reaction to a semi-permanent hyaluronic acid and acrylic hydrogel cosmetic filler. *Clin Exp Dermatol*. 2004;29:630-632.
224. Patrick T. Polyacrylamide gel in cosmetic procedures: experience with Aquamid. *Semin Cutan Med Surg*. 2004;23:233-235.
225. Lombardi T, Samson J, Plantier F, et al. Orofacial granulomas after injection of cosmetic fillers: histopathologic and clinical study of 11 cases. *J Oral Pathol Med*. 2004;33:115-120.
226. Haneke E. Polymethyl methacrylate microspheres in collagen. *Semin Cutan Med Surg*. 2004;23:227-232.
227. De Boulle K. Management of complications after implantation of fillers. *J Cosmet Dermatol*. 2004;3:2-15.
228. Bui P, Pons-Guiraud A, Kuffer R, et al. Slowly absorbable and non absorbable injectable products [in French]. *Ann Chir Plast Esthet*. 2004;49:486-502.
229. Bedir S, Kilciler M, Ozgok Y, et al. Long-term complication due to dextranomer based implant: granuloma causing urinary obstruction. *J Urol*. 2004;172:247-248.
230. Lemperle G, Morhenn V, Charrier U. Human histology and persistence of various injectable filler substances for soft tissue augmentation. *Aesthetic Plast Surg*. 2003;27:354-366; discussion 367.
231. Honig JF, Brink U, Korabiowska M. Severe granulomatous allergic tissue reaction after hyaluronic acid injection in the treatment of facial lines and its surgical correction. *J Craniofac Surg*. 2003;14:197-200.
232. Fernandez-Acenero MJ, Zamora E, Borbujo J. Granulomatous foreign body reaction against hyaluronic acid: report of a case after lip augmentation. *Dermatol Surg*. 2003;29:1225-1226.
233. Christensen LH, Breiting VB, Aasted A, et al. Long-term effects of polyacrylamide hydrogel on human breast tissue. *Plast Reconstr Surg*. 2003;111:1883-1890.
234. Friedman PM, Mafong EA, Kauvar AN, et al. Safety data of injectable nonanimal stabilized hyaluronic acid gel for soft tissue augmentation. *Dermatol Surg*. 2002;28:491-494.
235. Requena C, Izquierdo MJ, Navarro M, et al. Adverse reactions to injectable aesthetic microimplants. *Am J Dermatopathol*. 2001;23:197-202.
236. Teuber SS, Reilly DA, Howell L, et al. Severe migratory granulomatous reactions to silicone gel in 3 patients. *J Rheumatol*. 1999;26:699-704.